

# Prenatal Diagnosis of Isolated Lissencephaly by Ultrasonography and Magnetic Resonance Imaging: A Case Report

Mehmet Serdar KÜTÜK<sup>1</sup>, Mehmet DOLANBAY<sup>1</sup>, Mahmut Tuncay ÖZGÜN<sup>1</sup>, Hülya AKGÜN<sup>2</sup>, Ali YIKILMAZ<sup>3</sup>

Kayseri, Turkey

We present the abnormal sonographic findings in the brain of a 26-week fetus, which increased the suspicion of isolated lissencephaly. The woman had a history of prednisolone use in early pregnancy, and conceived with copper containing intra uterine device. Fetal magnetic resonance imaging and ultrasonography revealed hypoplastic cerebral parenchyma, and cortical agyria suggesting lissencephaly. Cordocentesis showed a normal 46, XY karyotype, and no deletion of chromosome 17 was detected. Post-mortem examination of the fetus confirmed prenatal US and MRI findings. Early detection of fetal microcephaly can be a sign of lissencephaly and need to be evaluated carefully with fetal MRI, and US.

**Key Words:** Lissencephaly, Ultrasonography, Prenatal, Agyria, Fetal

Gynecol Obstet Reprod Med 2014;20:53-55

## Introduction

Lissencephaly is a rare cortical dysplasia that results from impaired neuronal migration during the 12<sup>th</sup> and 16<sup>th</sup> weeks of gestation, characterized by a smooth cerebral surface, mental retardation, and seizures.<sup>1</sup> Since the prognosis for infants with lissencephaly is almost invariably poor, prenatal diagnosis at as early a stage as possible is of paramount importance to give the parents an appropriate counseling.

In the absence of family history, accompanying defects and related syndromes, prenatal diagnosis of lissencephaly is extremely rare.<sup>2,3</sup> We report here a case of isolated lissencephaly which was diagnosed prenatally by Ultrasonography (US) and fetal magnetic resonance imaging (MRI).

## Case Report

A 29- year old G4P3 woman was referred to our institution at 26 weeks of gestation. The presumptive diagnosis was that

<sup>1</sup> Erciyes University Faculty of Medicine Department of Obstetrics and Gynecology, Kayseri

<sup>2</sup> Erciyes University Faculty of Medicine Department of Pathology, Kayseri

<sup>3</sup> Erciyes University Faculty of Medicine Department of Radiology, Kayseri

*Address of Correspondence:* Mehmet Dolanbay  
Erciyes University, Faculty of Medicine  
Department of Obstetrics and  
Gynecology Gevher Nesibe Hospital  
Kayseri, Turkey  
mdolanbay@erciyes.edu.tr

*Submitted for Publication:* 06. 06. 2013

*Accepted for Publication:* 17. 09. 2013

of microcephaly. The woman and her husband were non-consanguineous and healthy, and there was no family history of congenital anomalies. The woman had a history of prednisolone use for acute angioedema at the fourth and 12<sup>th</sup> weeks in the present pregnancy. She had conceived with intra uterine device (Copper T380A) which was pulled out at 16<sup>th</sup> weeks.

Ultrasound examination (Voluson 730 Pro equipped with a 5- to 8-MHz transabdominal transducer, GE Healthcare) revealed biparietal diameter of 52 mm, and head circumference of 211 mm which were consistent with 23 gestational weeks, and thus microcephaly. At transverse sonogram, shallow and flat Sylvian fissure was detected (Figure 1A) and the parieto-occipital sulcus was not visualized (Figure 1B). No other anomalies were found and fetal growth and amniotic fluid volume were in the normal range. Fetal blood sampling by cordocentesis disclosed no congenital infection and a normal karyotype. Fetal MRI examination performed at 26 weeks of gestation showed elevated cranio-facial ratio, hypoplastic cerebral parenchyma, and cerebral agyria suggesting lissencephaly (Figure 1C). Fluorescent in situ hybridization studies revealed no absence on the short arm of the derivative segments of the chromosome 17p13 (LSI1) and 17.q21.1 (LSI RARA).

After the parents were informed of poor prognosis of the anomaly, they opted for termination of pregnancy. A 740 gr, male fetus was delivered. Postmortem examination of the fetus confirmed prenatal US findings, including microcephaly and lissencephaly (Figure 1D). Histopathological examination revealed four cortical cell layers rather than six that is consistent with lissencephaly which was consistent with lissencephaly (Figure 2).

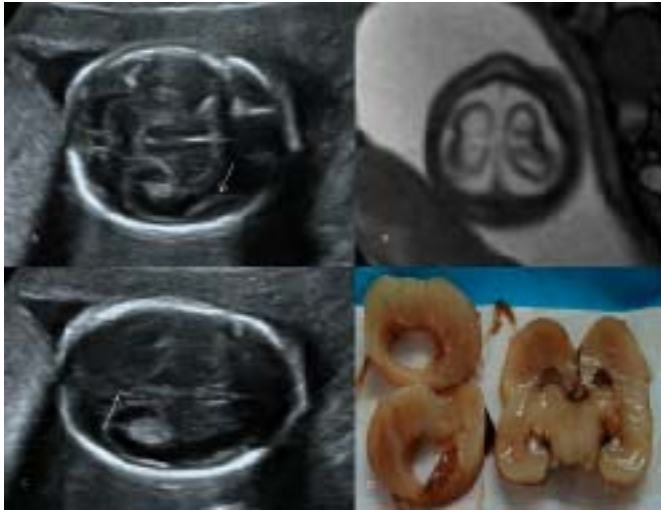

Figure 1A: Transverse ultrasonographic view of the fetal brain at 26 weeks showing smooth Sylvian fossa (arrow). B: Transverse ultrasonographic view of the fetal brain at 26 weeks showing absent parieto-occipital sulcus (arrow) development. C: Axial T2-weighted b-TFE image through the level of lateral ventricles. The gyri and sulci of the cerebrum are highly premature with respect to the age of the fetus. D: Postmortem examination of fetal brain showing complete absence of cortical sulci, and gyria at coronal sections.

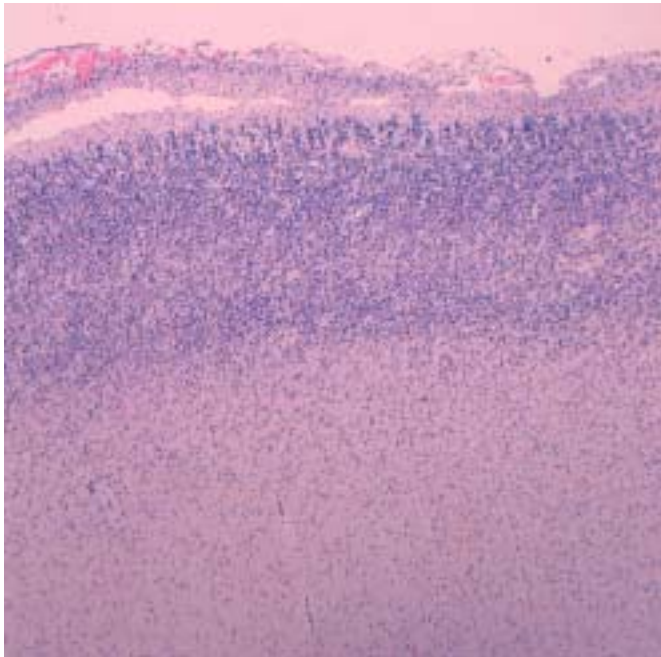


Figure 2: Photomicrograph of the brain cortex showing four cortical layers rather than six, and disorganized deep cortical cells that is consistent with lissencephaly Type 1 (Hematoxylin-eosin x40).

## Discussion

Lissencephaly is a rare developmental disorder due to impaired neuronal migration during the 3<sup>rd</sup> and 4<sup>th</sup> months of ges-

tation which results in either absence or reduction of cerebral convolution.<sup>1</sup> Two clinicopathological types have been identified.<sup>4</sup> Type 1 is characterized by a thick cortex with four rather than six layers of neurons, and it can be isolated or associated with phenotypes such as Miller-Dieker syndrome (MDS), or the Norman-Roberts syndrome, whereas type 2 is pathologically characterized by a disorganized, unlayered cortex, where hydrocephalus is a common feature, and the clinical presentation is the Walker-Warburg Syndrome.<sup>5</sup>

The developing brain is normally smooth until the onset of third trimester, and the opercularization of the insula is not complete until 27 to 28 weeks'. Therefore, the diagnosis of lissencephaly based on direct visualization of fetal cortex is not possible before the late third trimester.<sup>6</sup> However, Fang et al showed that, prenatal diagnosis of lissencephaly can be suspected from delayed and/or abnormal sulcal development on prenatal US before 24 weeks of gestation, with the findings such as absent parieto-occipital and calcarine fissures, and smooth, shallow Sylvian Fissure.<sup>7</sup> Additionally, accompanying defects such as ventriculomegaly, agenesis of the corpus callosum and Dandy-Walker malformation, usually raise the suspicion of this condition. Cases in which US examination is abnormal should be further investigated with MRI.<sup>8</sup> MRI can confirm the abnormally smooth Sylvian fissure/insula as well as the absence of parieto-occipital and calcarine fissures which can be seen on MRI by 22-23 weeks' gestation.<sup>9,10</sup> In the present case, microcephaly which is seen in 16% of fetuses with lissencephaly raised suspicion of cerebral cortical malformation which was subsequently confirmed by dedicated US and fetal MRI.<sup>11</sup>

Variety of environmental factors had been implicated in the etiogenesis of lissencephaly such as cytomegalovirus infection, prenatal trauma, x-ray exposure, diabetes mellitus and twin gestation.<sup>12,13</sup> Despite the presumed causal relationship between prenatal exposure to dexamethasone and fetal cortical maldevelopment,<sup>14</sup> no such relationship has been reported for prednisolone and fetal migrational defects. Genetic factors/mutations are the underlying cause for a considerable majority of patients with lissencephaly. In about 90% of patients with MDS structural defects have been confirmed in the short arm of chromosome 17 (p13.3), detectable by classical cytogenetic methods. The identification of unbalanced inversions and translocations is of particular importance because of the risk of their recurrence, while deletions and ring chromosomes are mainly sporadic. Syndromes featuring lissencephaly type II are most probably autosomal-recessively inherited.<sup>15</sup>

Children with severe grades of lissencephaly have a severe intellectual and motor disability and that the epilepsy is intractable in all cases.<sup>16</sup> Therefore, prognosis of lissencephaly

is universally poor, regardless of the etiologic types. Usually, the ultrasound diagnosis is made during the third trimester, and therefore, the option of pregnancy termination is determined by the local laws and traditions.

In conclusion, borderline fetal cranial US findings such as microcephaly or ventriculomegaly should be evaluated with dedicated fetal US and MRI to diagnose underlying severe cortical malformations and to present an appropriate prenatal counseling to the family.

## İzole Lizenfalinin Ultrasonografi ve Manyetik Rezonans Görüntüleme ile Prenatal Tanısı: Olgu Sunumu

Bu yazımızda 26 haftalık fetus beyinde izole lizenfalin şüphelenmemize neden olan anormal sonografik bulguları sunuyoruz. Hastamız bakır içeren rahim içi araç kullanırken gebe kalmıştı ve erken gebelik döneminde prednizolon kullanım öyküsü bulunmaktaydı. Fetal manyetik rezonans görüntüleme ve ultrasonografi lizenfaliyi destekleyecek biçimde hipoplastik serebral parankim ve kortikal agiriayı ortaya çıkardı. Kordosentezde 17. kromozomda delesyon yoktu ve normal 46 XY karyotipi saptandı. Fetusun ölüm sonrası incelemesi ultrasonografi ve manyetik rezonans görüntülemeyi destekler nitelikteydi. Erken saptanan fetal mikrosefali lizenfalinin bir bulgusu olabilir ve fetal MRI ve ultrasonografi ile dikkatlice incelenmelidir.

**Anahtar Kelimeler:** Lizenfali, Ultrasonografi, Prenatal, Agiria, Fetal

## References

1. Van der Knapp M, Valk J. Classification of congenital abnormalities of the CNS. *Am J Nucl Radiol* 1988;9:315-26.
2. Aslan H, Gungorduk K, Yildirim D, et al. Prenatal diagnosis of lissencephaly: a case report. *J Clin Ultrasound* 2009;37:245-8.
3. Greco P, Resta M, Vimercati A, et al. Antenatal diagnosis of isolated lissencephaly by ultrasound and magnetic resonance imaging. *Ultrasound Obstet Gynecol* 1998;12:276-9.
4. Dobyns WB, Stratton RF, Greenberg F. Syndromes with lissencephaly. I: Miller-Dieker and Norman-Roberts syndromes and isolated lissencephaly. *Am J Med Genet* 1984;18:509-26.
5. Aicardi J. The agyria-pachygyria complex: a spectrum of cortical malformations. *Brain Dev* 1991;13:1-8.
6. Monteagudo A, Timor-Tritsch IE. Development of fetal gyri, sulci and fissures: a transvaginal sonographic study. *Ultrasound Obstet Gynecol* 1997;9:222-8.
7. Fong KW, Ghai S, Toi A, et al. Prenatal ultrasound findings of lissencephaly associated with Miller-Dieker syndrome and comparison with pre- and postnatal magnetic resonance imaging. *Ultrasound Obstet Gynecol* 2004;24:716-23.
8. Ghai S, Fong KW, Toi A, et al. Prenatal US and MR imaging findings of lissencephaly: review of fetal cerebral sulcal development. *Radiographics* 2006;26:389-405.
9. Levine D, Barnes PD, Madsen JR, et al. Central nervous system abnormalities assessed with prenatal magnetic resonance imaging. *Obstet Gynecol* 1999;94:1011-19.
10. Okamura K, Murotsuki J, Sakai T, et al. Prenatal diagnosis of lissencephaly by magnetic resonance image. *Fetal Diagn Ther* 1993;8:56-9.
11. Entezami M, Albig M, Gasiorek-Wiens A, et al. Selected Syndromes and Associations. In: Entezami M, editor. *Ultrasound Diagnosis of Fetal Anomalies*. New York: Thieme; 2004, p 282.
12. Hayward JC, Titelbaum DS, Clancy RR, et al. Lissencephaly-pachygyria associated with congenital cytomegalovirus infection. *J Child Neurol* 1991;6:109-114.
13. Montenegro MA, Guerreiro MM, Lopes-Cendes I, et al. Interrelationship of genetics and prenatal injury in the genesis of malformations of cortical development. *Arch Neurol* 2002;59:1147-1153.
14. Korzhevskii DE, Gilerovich EG, Khozhai LI, et al. Modification of histogenetic processes in rat nervous tissue after administration of dexamethasone during prenatal development. *Neurosci Behav Physiol* 2006;36:537-9.
15. Miny P, Holzgreve W, Horst J. Genetic factors in lissencephaly syndromes: a review. *Childs Nerv Syst* 1993;9:413-7.
16. de Wit MC, de Rijk-van Andel J, Halley DJ, et al. Long-term follow-up of type 1 lissencephaly: survival is related to neuroimaging abnormalities. *Dev Med Child Neurol* 1993;35:417-21.